

THE EFFECTIVENESS OF
LASER
DIOXIDE
CARBON (CO₂)
FRACTIONAL IN
TREATMENT OF
RED STRETCH MARKS AND
ALBUS STRETCH MARKS

THE
EFFECTIVENESS
OF
FRACTIONATED
CARBON DIOXIDE
(CO₂) LASER IN
THE TREATMENT
OF RED STRETCH
MARKS AND STRETCH
MARKS

SOUZA, Wanessa De Oliveira
[1]

[1] Master's student in health sciences, graduating in biomedicine from Faculdade Joaquim Nabuco (UNINABUCO), graduated in Aesthetics from Fundação Mineira de Educação e Cultura (FUMEC), Postgraduate in advanced aesthetics and distance education from Uniasselvi and Postgraduate in acupuncture from Faculdade da Região Serrana (FARESE).
wanessadeoliveirasouza@gmail.com

SUMMARY

The research carried out consisted of analyzing the effectiveness of the fractional CO₂ laser in the treatment of stretch marks. Stretch marks are one of the main aesthetic changes to the body. Stretch marks are an atrophic aesthetic lesion, caused by enormous stretching and the consequent rupture of collagen and elastin fibers, responsible for the skin's elasticity. They affect a large portion of the population, being more common in adolescent and pregnant women, although it can also occur in obese people, patients with hormonal imbalances, medication users and those with a genetic history. Treatments for stretch marks vary according to the stage of evolution of the stretch mark and the patient's skin phototype. Among the most sought after is the fractional CO₂ laser, its action consists of promoting tissue damage through thermal damage and vaporization of cells, leading to the stimulation of neocollagenesis, with the water present in the tissues as its main target. The purpose of the study carried out was to evaluate the effectiveness of using the fractional CO₂ laser in the treatment of red and white stretch marks, identifying its benefits, describing its mechanism of action and analyzing the results presented in the scientific literature. To this end, a bibliographical search was carried out in the main databases, the virtual health library (bvs); scientific electronic library online (scielo), Google scholar and lilacs. Concluding, therefore, that the fractional CO₂ laser is effective for the treatment of stretch marks, however, attention is needed with the patient's phototype due to the complications that may occur, such as hyperpigmentation, post-inflammatory, persistent hyperpigmentation, scars, burns and Koebner syndrome.

Key words: Skin. Stretch marks. Fractional CO₂ laser. Aesthetics.

ABSTRACT

The research developed consisted of analyzing the effectiveness of fractional CO₂ laser in the treatment of stretch marks. Among the main aesthetic changes in

the body, this one is like stars. The stretch mark is an atrophic aesthetic lesion, caused by a huge stretch and a consequent rupture of the collagen and elastin fibers, responsible for the elasticity of the skin. They affect a large portion of the population, being more frequent in adolescents and pregnant women, although it can also be present in obese people, patients with hormonal imbalances, users of medications and patients with a genetic history. The treatments for stretch marks vary according to the stage of evolution of the stretch and the phototype of the patient's skin. Among the most sought after is the fractional CO₂ laser, its practice consists of promoting tissue damage through thermal damage and vaporization of cells, leading to the stimulation of neocollagenesis, with the main target being the water present in the tissues. The purpose of the study was to evaluate the effectiveness of using fractional CO₂ laser in the treatment of red and white streaks, identifying its benefits, describing its mechanism of action and analyzing the results obtained by the scientific literature. To this end, a bibliographic search was carried out in the main databases, a virtual health library (bvs); online electronic scientific library (scielo), academic Google and lilacs. Therefore, concluding that fractional CO₂ laser is effective for the treatment of stretch marks, however, attention is needed with the patient's phototype due to complications that may occur, such as post-inflammatory hyperpigmentation, persistent hyperpigmentation, scarring, burns and Koebner syndrome.

Keywords: Skin. Stretch marks. Fractional CO₂ laser. Aesthetics.

1. INTRODUCTION

The modern world is circumscribed by the tribute to the body and the incessant search for beauty standards dictated by the media, in a way that affects the relationship that individuals build with their own body, resulting in emotional compromise, low self-esteem and dissatisfaction with their own appearance (DANTAS, 2011; QUEIROZ, RODRIGUES, DE CONTE, 2021). Aesthetics is in the spotlight, given the enormous demand for aesthetic treatments in a society that prioritizes health and values body appearance. There are countless reasons that lead an individual to develop dissatisfaction with their own image. Stretch marks are among the main aesthetic changes in the body (QUEIROZ; RODRIGUES; DE CONTE, 2021).

Stretch marks are an atrophic aesthetic injury, caused by excessive distension and the consequent rupture of collagen and elastin fibers, responsible for the skin's elasticity (TACANI; TACANI, 2011). They affect a large portion of the population, being more common in females and during puberty, although it can also occur in obese people, pregnant women, medication users and those with hormonal imbalances (BORGES; SCORZA; JAHARA, 2010; DA COSTA, 2016; COSTA, 2016; There is evidence that reports that its manifestation is due to the association of factors

mechanical, endocrinological, genetic predisposition and family history (REZENDE; PINHEIRO; MENDONÇA, 2016; LOPES, 2017). The areas with the greatest presence of stretch marks are the breasts, buttocks, abdomen and thighs, as they are areas more sensitive to exaggerated stretching of the skin (DOS REIS; VIEIRA, 2018).

In this context, there are several aesthetic therapeutic resources developed by the market to reach this consumer audience that intends to improve body image (PETROSKI; PELEGRINI; GLANER, 2012). Treatments for stretch marks vary according to the stage of evolution and the patient's phototype. Among the most sought after is the fractional CO₂ laser (DOS REIS; VIEIRA, 2018). Its action consists of promoting tissue damage through thermal damage and vaporization of cells, leading to the stimulation of neocollagenesis, with the main target being water present in tissues (CROCCO; MANTOVANI; VOLPINI, 2012; DOS REIS; VIEIRA, 2018).

Given this scenario and taking into account that the fractional CO₂ laser is currently being used in rhytides, facial rejuvenation, acne scars and stretch marks, this article hopes to verify the effectiveness of the fractional CO₂ laser in the treatment of stretch marks (CROCCO ; MANTOVANI; VOLPINI, 2012;

Considering that none of the treatments currently used for stretch marks have been considered the gold standard, and that there is a great demand from clients who seek centers specialized in aesthetics to alleviate this condition, demonstrating the need for more studies that prove the true effectiveness of the current aesthetic procedures used for this purpose; the fractional CO₂ laser was chosen as the object of study of this article, due to the lack of scientific materials relating its use for stretch mark treatments (EL TAIEB; IBRAHIM, 2016; LOPES, 2017; COSTA, 2016; NEPOMUCENO; DA- SILVA, 2018), the research problem has as its guiding question: How effective is the fractional CO₂ laser in treating stretch marks?

To answer the guiding question presented in the research problem, this study aimed to evaluate the effectiveness of using the fractional CO₂ laser in the treatment of red and white striae; and, specifically identify the benefits of using fractional CO₂ laser in the treatment of stretch marks; describe its mechanism of action and analyze the results presented in the scientific literature. This research is justified by considering it important to appropriate literature to advance knowledge regarding the use of fractionated CO₂ laser as an effective therapeutic resource in the treatment of stretch marks.

After an analysis of the specialized literature, it was reflected that, however, there are not enough scientific studies on the fractional CO₂ laser to support its use in the treatment of stretch marks, and when analyzing its mechanism of action, it is considered that its use could be effective for treating stretch marks.

2 THEORETICAL FOUNDATION

2.1 ANATOMY, HISTOLOGY AND PHYSIOLOGY OF THE SKIN

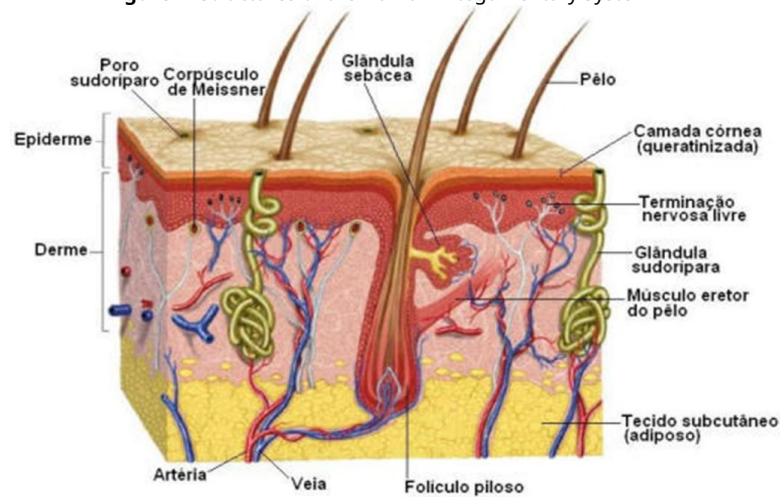
The skin is the largest organ in the human body as it covers the entire body surface, weighing approximately 4.5 kg, representing 15% of human body weight. It has specialized, flexible, resistant and complex structures, being responsible for several functions of significant importance, including perspiration, perception, physical and immunological protection, pigmentation, nutrition, keratogenesis, defense, metabolism, absorption, secretion, excretion and thermoregulation, as the skin behaves as a thermal insulator, regulating water and electrolyte loss from the body, resulting in the conservation of body temperature (FONTENELE; CARDOSO, 2011; KHAVKIN ; ELLIS,2011; COSTA, 2016; VENUS; WATERMAN; MCNAB, 2010; NAYLOR; WHATSON; SHERRATT, 2011; GONDIM, 2012; DA COSTA, 2016).

The skin acts as an enveloping and insulating membrane, a physical barrier against external aggressions, reducing the penetration of foreign, chemical and harmful substances, protecting against the action of pathogenic microorganisms and ultra violet radiation, in addition to its capacity for tissue regeneration, a process complex that aims to restore the integrity of the injured tissue, an important factor for the results in the treatment of stretch marks (FONTENELE; CARDOSO, 2011; KHAVKIN; ELLIS,2011; COSTA, 2016; VENUS; WATERMAN; MCNAB, 2010; NAYLOR; WHATSON; SHERRATT, 2011; GONDIM, 2012; DA COSTA, 2016).

Sensory and autonomic nerves are a structural part of the skin, they are necessary for detecting touch, vibration, pressure, temperature, pain and itching, their biomechanical properties act in response to deformation force (VENUS; WATERMAN; MCNAB, 2010; KHAVKIN; ELLIS, 2011; COSTA, 2016). The skin is made up of three overlapping layers of tissue. The epidermis is the outermost layer and is the main barrier to

defense, the intermediate one is the dermis, very vascularized, and the deepest layer is the hypodermis, made up of adipose tissue. In figure 1 it is possible to observe these three layers. They perform their activities independently, undergoing regulation, molecular and cellular modeling as they perform their functions. Water makes up approximately 70% of the skin, distributed throughout the layers, with the hypodermis being the most hydrated, it also contains proteins, lipids, carbohydrates and mineral salts (GONDIM, 2012; KHAVKIN; ELLIS, 2011; VENUS; WATERMAN ; MCNAB 2010 ; COSTA , 2016; DA COSTA, 2016; LOPES, 2017).

Figure 1- Structures of the Human Integumentary System



Source: (Oliveira, 2011).

2.1.1 Epidermis, dermis and hypodermis

According to Borges; Scorza; Jahara (2010), the epidermis is composed of stratified squamous epithelium that is continually renewed. Due to the fact that it is avascular, the capillaries of the superficial dermis nourish the epidermis by diffusion. Its cellular composition is mainly keratinocytes (>90%), which regulate homeostasis and the constant renewal of epidermal hair follicles (KHAVKIN; ELLIS, 2011; VENUS; WATERMAN; MCNAB, 2010; COSTA, 2016; DA COSTA, 2016; GONDIM, 2012; CAUSSA; VILA, 2015; Keratinocytes, through their constant differentiation, renew the epithelium throughout life through keratinization, they progressively move from the basement membrane to the surface of the skin, where they peel off, forming several distinct layers along this path, figure 2, they are: the basal or germinative stratum, the most

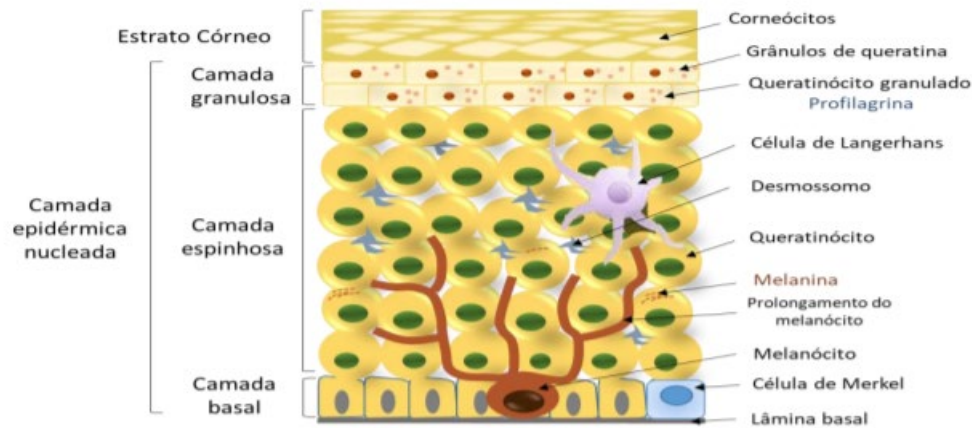
deep, connected to the dermis by hemidesmosomes that are attached to the basement membrane, this stratum is made up of a single layer of keratinocytes, mostly interspersed with Merkel cells and melanocytes, with melanocytes being responsible for the production of melanin, which gives skin pigmentation. . From the division of these cells, the KHAVKIN stratum granulosum is formed; ELLIS, 2011; VENUS; WATERMAN; MCNAB, 2010; COSTA, 2016; DA COSTA, 2016; GONDIM, 2012; CAUSSA; VILA, 2015; LOPES, 2017).

The stratum spinosum or Malpighi is located on the stratum basale and consists of 8 to 10 layers of cells, contains desmosomes and Langerhans cells that participate in immune function. The stratum granulosum precedes the spinous one and is made up of 2 to 5 layers of flattened cells with a granular structure due to the presence of keratohyalin grains that act as a barrier and participate in cohesion between cells due to their high amount of lipids, phospholipids and proteins. On the surface of this stratum, the nucleus and organelles of the cell disintegrate and the cell dies, forming the stratum corneum (KHAVKIN; ELLIS, 2011; VENUS; WATERMAN; MCNAB, 2010; COSTA, 2016; DA COSTA, 2016; GONDIM, 2012, LOPES, 2017).

The stratum corneum is the most superficial layer of the epidermis and contains several layers of dead squamous cells, united by desmosomes, called corneocytes, they are dead, anucleated and keratinized keratinocytes, they are rich in keratin, lipids and water, forming an impermeable barrier (KHAVKIN ; ELLIS, 2011; GONDIM; MCNAB, 2010;

The thickness of the stratum corneum can vary according to the region of the body, reaching 1.5 mm on the soles of the feet and palms of the hands, where it gains an additional palmoplantar layer, the stratum lucidum, this layer is composed of dead, homogeneous cells and translucent whose function is protection. Cell renewal lasts approximately 28 days, and may undergo changes caused by pathological processes (KHAVKIN; ELLIS, 2011; LOPES, 2017; VENUS; WATERMAN; MCNAB, 2010; COSTA, 2016; DA COSTA, 2016; GONDIM, 2012).

Figure 2- Layers of the epidermis.



Source: (SOUSA, 2018).

According to Naylor; Watson; Sherratt (2011), the dermis is composed of an amorphous fundamental substance, horny skin annexes and several cells, among them, we have fibroblasts, responsible for the synthesis of collagen and elastin, it is located above the hypodermis and below the epidermis, united to it through the dermoepidermal junction, a structure composed of fibroblasts, which form collagen and elastin that offer resistance against external forces that cause deformation, serving as an impermeable barrier, and signaling for tissue growth and regeneration. The dermis has variable thickness and great resistance against mechanical aggression. It contains vascular and nervous structures, sebaceous and sweat glands and hair follicles. Underneath the dermis, there is also the hypodermis, formed by fibrous, elastic and fatty tissues. (VENUS; WATERMAN; MCNAB, 2010; COSTA, 2016; DA COSTA, 2016; GONDIM, 2012; FONTENELE; CARDOSO, 2011).

Collagen is the most abundant and functional protein present in the human body, it constitutes the extracellular framework in all living beings, offers resistance and structural integrity to various organs and tissues, it also acts in the healing process and/or tissue regeneration, in addition to helping in skin hydration. There are nineteen distinct classes of collagen, distributed between types I to XIX. Type I is the most abundant in the human body, it is the most important for tissue elasticity, while type IV integrates the dermoepidermal junction and basement membrane. Collagen represents 30% of the total dermis and 75% of this is formed by type I and type III collagen (VENUS; WATERMAN; MCNAB, 2010; GONÇALVES *et. al.*, 2015; COSTA, 2016).

Elastin is a fibrous protein with elastic resistance that allows the skin to recover its original shape after being pulled. These fibers are thin in the papillary dermis, allowing vertical branches in relation to the epidermis, and thick with a horizontal orientation in the reticular dermis (WANG et al, 2015; GONÇALVES *et. al.*, 2015; COSTA, 2016). Elasticity is the skin's ability to return to its initial state, after the forces that cause this extension cease. This capacity depends on the activity of elastic and collagen fibers, and the hydration state of the fundamental substance, determining the importance of maintaining the skin's water content (LOPES, 2017).

The dermis is segmented into superficial or papillary dermis, located at the dermoepidermal junction, it is very vascularized, rich in fibers and nerve endings, enabling metabolic exchanges with the germ layer, it has several cells and thin fibrillar bundles; the deep or reticular dermis, is located in the lower part of the dermis, it is composed of large bundles of collagen, and finally the adventitial dermis, made up of thin bundles of collagen, distributed between the appendages and vessels (HWANG; YI; CHOI, 2011; LOPES, 2017; *et. al.*, 2016; DA COSTA, 2016; VENUS; WATERMAN; MCNAB, 2010; GONDIM, 2012; FONTENELE; CARDOSO, 2011; COSTA, 2016).

The hypodermis is the deepest layer of the skin located below the reticular dermis, relating in its upper portion to the deep dermis, constituting the dermo-hypodermal junction. The hypodermis has variable thickness and is made up exclusively of adipocytes, collagen and blood vessels, which are larger in caliber than those of the dermis. It behaves like a subcutaneous tissue, subcutaneous tissue or superficial fascia. It functions as an energy reservoir called adipose tissue, a thermal insulator that, in addition to cushioning the skin, allows its mobility over adjacent tissues (FONTENELE; CARDOSO, 2011; COSTA, 2016; GONDIM, 2012; LOPES, 2017; DA COSTA, 2016).

The distribution of adipose tissue is not uniform in all regions of the body, some regions may not accumulate fat, such as the eyelids, the umbilical scar, the sternum region, the penis, and the joint folds. In other regions, on the other hand, there is greater accumulation of adipose tissue: the proximal portion of the limbs and the lateral portions of the abdominal wall (FONTENELE; CARDOSO, 2011; COSTA, 2016; GONDIM, 2012; DA COSTA, 2016).

2.2 HISTOLOGY

Histology studies the body's tissues and organic fluids that contain cells. Several cells and the extracellular matrix form tissues. There are a variety of tissues in the human body, they are divided into four groups: epithelial tissue, connective tissue, muscular tissue and nervous tissue. Epithelial and connective tissues are the main tissues found in the skin, in the epidermis and dermis layers (DA COSTA, 2016; LOPES, 2017; COSTA, 2016).

2.2.1 Epithelial tissue and connective tissue

Epithelial tissue is composed of cells joined together by the extracellular matrix. The lining epithelium and the glandular epithelium are fundamental categories of epithelial tissue, they differ according to their structure and functions. The lining epithelium surrounds the internal and external cavities of the human body, covering the internal portion of the oral cavity, nasal cavities, stomach and intestines, and the external portion is the epidermis. Epithelial tissue is classified according to the number of cell layers, and can be simple epithelium, with a single layer of cells or stratified with more than one cell layer. Simple and stratified epithelia can be subdivided into squamous (flat), cubic and prismatic, according to the shape of their cells (DA COSTA, 2016; LOPES, 2017; COSTA, 2016).

Connective tissue has fibroblasts, macrophages, lymphocytes, plasma cells, mast cells, adipocytes and leukocytes, separated by an abundant extracellular material or fundamental substance. It is classified into loose and dense connective tissue, loose connective tissue is found in the skin, mucous membranes and glands. , the dense is found in muscle tendons. The main fibers of the connective tissue are collagen, reticular and elastic. Collagen fibers make up 95% of the connective tissue of the dermis, being thinner and looser in the papillary dermis and thicker and more compact in the reticular dermis (DA COSTA, 2016; LOPES, 2017; COSTA, 2016).

Collagen can be classified according to its structure and function into fiber-forming collagens, fiber-associated collagens, network-forming collagens, and anchoring collagens. The collagen that forms the fibers comes together to synthesize them, they belong to this

group collagens types I, II, III, V and XI. Type I is the most numerous collagen in the human body, present in bones, dentin, tendons, coverings of numerous organs, dermis, among others. The collagen associated with the fibers fuses the collagen fibers with each other and with the elements of the extracellular matrix. Type IX and XII collagens participate in this group. The collagen that forms the network is one of the main members of the basal lamina, being type IV, and the anchoring collagen is type VII, it joins the type I collagen to the basal laminae (DA COSTA, 2016; LOPES, 2017; COSTA, 2016).

Collagen fibers provide tensile strength to injuries during the healing phase. In healthy tissues, metabolism is reduced to homeostasis between biosynthesis and degradation. When tissue injury occurs, fibroblasts do not divide, but during tissue repair they enter mitosis to heal the injury and carry out the synthesis of collagen and elastic fibers (DA COSTA, 2016; LOPES, 2017; COSTA, 2016).

Reticular fibers are similar to collagen fibers, as they also form fibrils, but with a striated appearance and are composed of type III collagen, however they differ from reticular fibers in that they are thinner and in the form of a network, not forming thick fibers. Reticular fibers are in loose connective tissue, associated with epithelia, small blood vessels, nerves and muscle cells, short, thin and inelastic. Reticular fibers are distinct from elastic fibers; reticular fibers are thinner and do not have longitudinal striation (DA COSTA, 2016; LOPES, 2017; COSTA, 2016).

Elastic fibers are thin, yellowish in color and have elastin as their main component. It is much more resistant than collagen and elastic microfibrils, it yields to large traction forces and is capable of easily returning to its original appearance. Elastin is a short, overlapping elastic fiber, manufactured by a precursor secreted by fibroblasts, such as collagen, being responsible for the elasticity of the skin, capable of distensibility of 100 to 140%. Anomalies related to elastic fibers can be found in the skin of the elderly, young diabetics or those with atrophic stretch marks (DA COSTA, 2016; LOPES, 2017; COSTA, 2016).

2.3 TISSUE REPAIR PROCESS

In accordance with the Education Portal (2021) the tissue repair process, also called scarring, is a very complex phenomenon, which aims to

restoring the morphology and functionality of an injured tissue is a systematized cascade of events that interact so that tissue restoration occurs. This process depends on factors related to the type of skin, the location of the tissue to be repaired, the age of the patient, the patient's general and nutritional health, the type of tissue injury and the level of dryness of the skin during repair.

The healing process is subdivided into phases, namely the inflammatory phase, the proliferative phase and the remodeling phase. These phases are interdependent and occur simultaneously. It begins with the inflammatory phase, which starts from the moment tissue damage occurs and lasts for 24 to 48 hours, characterized by heat, redness, edema and pain, with the possibility of partial or total loss of cellular functions. , the injured area is also cleaned, with the removal of devitalized tissues and the migration of lymphocytes, chemical mediators, neutrophils and macrophages. Macrophages phagocytose tissues without vitality, secrete chemotactic agents that attract other inflammatory cells to the site of injury and produce prostaglandins, which are potent vasodilators that affect the permeability of microvessels (ALBUQUERQUE, *et. al.*, 2010; EDUCATION PORTAL, 2021).

The second phase is proliferative, in which the lesion closes. It is subdivided into three subphases: Re-epithelialization, when keratinocytes from the sides of the lesion and epithelial attachments migrate to the lesion. The second subphase is fibroplasia, when the formation of elastin and collagen type III occurs, immature, disorganized and with little resistance, and finally, angiogenesis, the last subphase when the formation of new tissue and creation of new vessels occurs. . Granulation tissue and new vessels together with macrophages, fibroblasts and epithelial cells will fill the wound, the wound contracts reducing its diameter. The proliferative phase lasts from three days to three weeks (ALBUQUERQUE, *et. al.*, 2010; EDUCATION PORTAL, 2021).

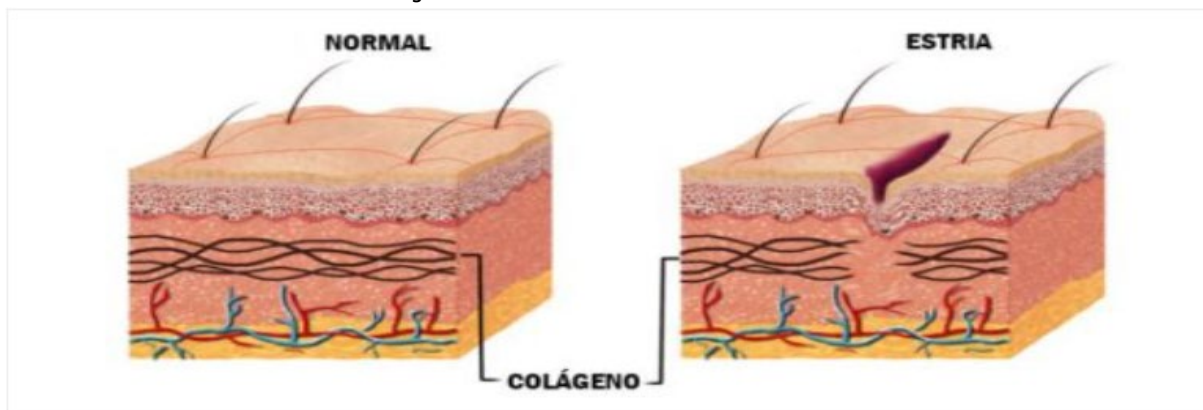
Remodeling is the third and final phase of healing, it is the largest phase and can last for years, in which the collagen fibers of the scar tissue are realigned, reducing the scar and increasing the tension force, this occurs due to the replacement of type III collagen by type I that passes and is organized and functional (ALBUQUERQUE, *et. al.*, 2010; EDUCATION PORTAL, 2021).

2.4 CHANGES IN THE STRUCTURE OF THE EPIDERMIS AND DERMIS

Changes in these structures cause changes in the thickness of the connective tissue, which, combined with greater tension on the skin, produces skin striations. The elastic fibers in recent lesions are striated and in old lesions, they dismember and concentrate in isolated locations, explaining this slight depression in the skin texture that is visible in striae alba. There are three classes of dermal lesions that present different changes in elastic and collagen fibers, in the amorphous ground substance and in fibroblasts. These are atrophic striae, senile lesions of the papillary dermis, senile lesions of the reticular dermis and scars (ALBUQUERQUE, *et. al.*, 2010; EDUCATION PORTAL, 2021).

Stretch marks are a benign cutaneous degenerative process that varies in color depending on its stage of evolution. It is clinically characterized by linear, atrophic and superficial morphology, with discreet undulations and minimal wrinkles that disappear when pulled. Its clinical evolution is similar to the healing phases, compared to normal-looking skin. They have a reduction in collagen and elastic fibers, figure 3, and may initially appear red, that is, with a reddish or pale appearance, but after 4 to 18 months they become whitish or pearly. The color variation depends on the presence or absence of microvascular components, the size and activity of melanocytes and the patient's phototype, higher phototypes tend to have Hyperchromic striae (DA COSTA, 2016; COSTA, 2016; MAIO, 2016; ALBUQUERQUE, *et. al.*, 2010; EDUCATION PORTAL, 2021).

Figure 3-Normal skin and skin with stretch marks



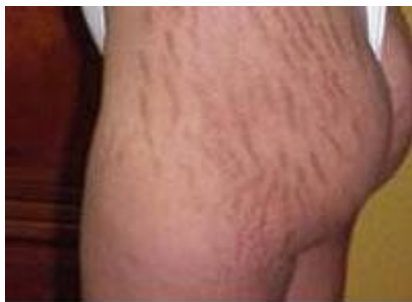Source: (ALDAHAN *et. al.*, 2016)

2.4.1 Atrophic striae and distensive striae

In 1773 Roederer carried out the first clinical study of stretch marks in pregnant women, in 1989, Troisier and Menetrier named stretch marks as a harmless and disfiguring disease, Unna in 1984 created the hypothesis that endogenous factors influence the elastic fibers of connective tissue and in 1936 Nardelli named such as atrophic stretch marks and nowadays stretch marks continue to be a challenge for professionals when it comes to evaluation and treatment (ALBUQUERQUE, *et. al.*, 2010; EDUCATION PORTAL, 2021; DA COSTA, 2016; MAY, 2011; BUCHANAN; FLETCHER; REID, 2010).

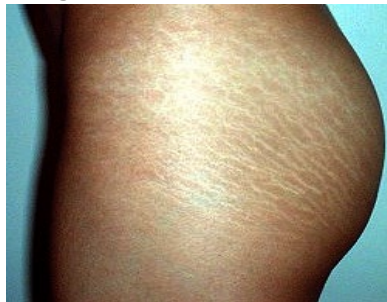Atrophic striae have a scarring appearance, hypochromia and central flaccidity, creating a medium depression. Striae alba or nacreous are mature striae that are also considered atrophic, figure 5. Striae red are recent and erythematous due to increased local vascularization, figure 4. As regards striae cerulas, they have a bluish color and are common in people with Cushing's syndrome or users of corticosteroids for long periods, figure 6. The blackish stretch marks are called striae nigra, they appear in individuals with phototypes IV and V, figure 7 (ALBUQUERQUE, *et. al.*, 2010; EDUCATION PORTAL, 2021).

Figure 4-Red Stretch Marks



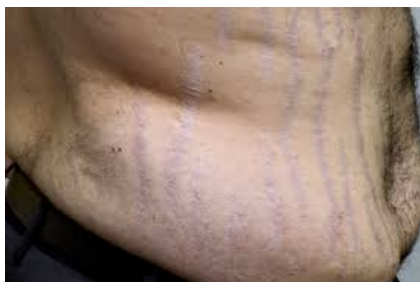Source: AL-HIMDANI *et. al.*, 2012

Figure 5-Striae Albas



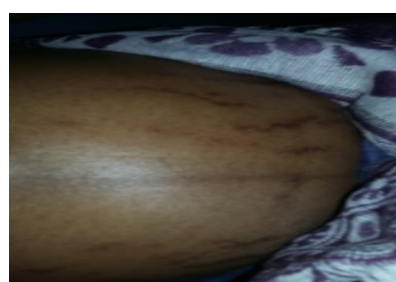Source: BUCHANAN; FLETCHER; REID, 2010

Figure 6-cerulean stretch marks



Source: COSTA, 2016

Figure 7-Striae Nigra



Source: FAAD, 2015

To the *striae distensae* They are distension striae, established as acquired integumentary atrophy that propagate in the dermis, their elastic fibers are scarce in the peripheral region of the stria and non-existent in the central region. They are named atrophic due to their characteristics, as atrophy is a decrease in skin thickness, and stretch marks are caused by the rupture of collagen and elastic fibers in the dermis. They tend to be symmetrical and bilateral and can appear on all skin types. It has different nomenclatures taking into account the language, etiology, appearance of the skin, and according to the situation in which they occur, popularly known as striae, they can be distension striae (*striae distensae*), atrophic striae, *striae gravidarum* (*striae gravidarum*), *striae albicante* and *striae infectiosae* (ALBUQUERQUE, *et. al.*, 2010; EDUCATION PORTAL, 2021; DA COSTA, 2016; MAY, 2011; BUCHANAN; FLETCHER; REID, 2010).

2.4.2 Striae Gravidarum

During pregnancy, endocrinological, immunological, metabolic and vascular changes occur that affect the entire body, including the skin. Stretch marks occur during pregnancy due to mechanical, genetic and hormonal factors, in addition to family history, skin color and phototype, pregnant woman's age, gestational age, fetal weight, diabetes, maternal weight and the presence of stretch marks prior to pregnancy. Gestational stretch marks are benign skin changes that affect 50 to 90% of pregnant women. They generally occur from the second trimester of pregnancy and are preferred in the abdominal region, breasts, buttocks, thighs and armpits. Pregnant women may experience local itching from the stretch marks and if the pregnant woman scratches it, it can damage the area and cause infection. Pregnant women with *striae gravidarum* can suffer negative psychological impacts, resulting in decreased self-confidence and distress. These injuries are difficult to prevent and treat (VORA *et. al.*, 2014; TAAVONI *et. al.*, 2011; UD-DIN *et. al.*, 2013; COSTA, 2016; WANG, *et. al.*, 2015; NARIN *et. al.*, 2015; BUCHANAN; FLETCHER; REID, 2010; SOLTANIPOUR *et. al.*, 2014).

2.4.3 Stretch marks evolution stages

Red striae refer to the acute stage of striae evolution, they are called immature, figure 4. They are erythematous, reddish and slightly elevated lesions,

They can be symptomatic, with the presence of itching, burning and discomfort or be asymptomatic, they are perpendicular to the direction of skin tension. In the chronic stage, stretch marks are atrophic, wrinkled and hypopigmented, that is, there is no melanization process, they are parallel to the skin's tension line, they are called striae alba or mature, figure 5. They are generally asymptomatic, but in rare cases may present with urticaria, edema, depigmentation, ulceration, dehiscence and subcutaneous emphysema. In individuals with white skin, stretch marks begin as pink erythematous lesions with a smooth and tense surface and gradually lose their pigmentation, becoming atrophic and white (LOPES, 2017; UD-DIN; MCGEORGE; BAYAT, 2016; DEVILLERS *et. al.*, 2010; ERSOY *et. al.*, 2016; ROSS *et. al.*, 2017; AL-HIMDANI *et. al.*, 2014; NAPOMUCENE; DA-SILVA, 2018; COSTA, 2016; SAVAS *et. al.*, 2014; WANG *et. al.*, 2015 GILMORE *et. al.*, 2012).

2.4.4 Etiology, epidemiology and histopathogenesis of stretch marks

To date, however, the causes for the appearance of stretch marks are not really known, however there are theories that strive to justify their etiology. The mechanical theory emphasizes that the fact that the skin suffers stretching, rupture or loss of its dermal elastic fibers, whether due to excessive and/or sudden increase in body area, demonstrating a possible mechanism for the emergence of stretch marks, as in cases of obesity and its excessive increase in adipose tissue, which can also occur during pregnancy, puberty, vigorous physical activity and growth. The endocrinological theory is based on the understanding that the therapeutic use of adrenal cortical hormones, increased production of glucocorticoids, the indiscriminate use of anabolic steroids, biochemical nutritional disorders, hormonal disorders and iatrogenic disorders are associated with the appearance of stretch marks with a localized effect in some body regions (COSTA, 2016; *et. al.*, 2015; FAAD; MD, 2015; LOPES, 2017; FARAHNIK, *et. al.*, 2017).

The infectious theory advocates that infectious processes are the ones that cause damage to elastic fibers and are therefore responsible for the appearance of stretch marks. There are reports of the appearance of stretch marks after typhoid fever, rheumatic fever and other infections, in addition to chronic liver diseases, chronic hepatitis, Marfan syndrome, Cushing's syndrome, pseudo xanthoma elasticum, cachexia and Buschke Ollendorf syndrome. Genetic and familial predisposition would be the genetic theory, as it is assumed that the expression of genes determining

formation of collagen, elastin and fibronectin would be reduced in patients with this condition, altering the metabolism of fibroblasts or causing a deficiency in connective tissue (COSTA, 2016; NARIN*et. al.*, 2015; ROSS*et. al.*, 2017; LOPES, 2017).

Regarding the hormonal theory, it is based on the understanding that steroid hormones would influence the catabolic activity of fibroblasts, thus reducing the amount of collagen in the dermal matrix, thus changes in the concentrations of estrogens, androgens and glucocorticoids explaining the fact that adolescents and pregnant women are in the high-risk group for the appearance of stretch marks, and are also associated with rapid growth and weight gain, in addition to the hormonal changes that occur (COSTA, 2016, NARIN*et. al.*, 2015; WANG*et. al.*, 2015; LEDOUX*et. al.*, 2011; ROLFE; WURM; GILMORE, 2012; LOPES, 2017). Pregnant women, adolescents and people with endocrine diseases are considered the groups most predisposed to the development of stretch marks, due to hormonal, mechanical and endocrine factors respectively. Stretch marks are more common in females than in males, with a preference for black people, and is more common in young pregnant women, generally appearing around the sixth and seventh month of pregnancy, but there are reports of before 24 weeks of gestation. Stretch marks may have a higher incidence in smokers than non-smokers (ROSS,*et. al.*, 2017; LOPES, 2017; SAVAS*et. al.*, 2014).

At the tissue level, the skin normally presents with small bundles of collagen and elastin fibers that gradually increase in thickness towards the deeper layers of the skin. The moment stretch marks become visible on the skin, it is a sign that changes have occurred in collagen, elastin and fibrillin, components of the skin that provide tensile strength and elasticity. In red striae, the tissue fibers are thin and in large quantities in the papillary dermis and thick and disorganized in the periphery, the dermal vessels are dilated, there may be edema and the presence of perivascular lymphocytes. Elastin and fibrillin fibers reduce their quantity and are reorganized, structural changes occur in the collagen fibers, becoming dense and compact in parallel lines. (HAGUE; BAYAT, 2017; LOPES, 2017).

In striae alba you can see epidermal atrophy, little vascularization and the horizontal collagen fibers are dense, compacted, thin, fragmented and have a scarring appearance. The epidermis is thinner and flatter, the elastic fibers are separated and fragmented, the mast cells undergo degranulation which results in the activation of macrophages, intensifying

elastolysis. Fibrillin from the dermoepidermal junction and papillary dermal elastin decrease in quantity and elastin and fibrillin fibers from the reticular dermis realign themselves, producing the atrophic appearance of striae alba (HAGUE; BAYAT, 2017; LOPES, 2017; REZENDE; PINHEIRO; MENDONÇA, 2016; KASIELSKA-TROJAN; *et. al.*, 2012; SAVAS *et. al.*, 2014; WANG *et. al.*, 2015; UD-DIN *et. al.*, 2013).

2.4.5 Methods for evaluating stretch marks before and after the procedure

Visual methods and methods with imaging devices are used to evaluate striae. Davey's method is visual, the abdomen is divided into quadrants using vertical and horizontal lines, using the umbilical scar as a central reference, and then each quadrant is evaluated for the number of stretch marks, with 0 being absent, 1 being moderate, 2 being lots of. The Atwal score is also a visual method that quantifies the presence of stretch marks and erythema on the abdomen, hips, breast, thighs and buttocks. Being 0 for absence of striae and/or absence of erythema, 1 for <5 striae and/or presence of light red erythema, 2 for 5-10 striae and/or dark red erythema and 3 for > 10 striae and/or purple erythema (AL-HIMDANI *et. al.*, 2014; LOPES, 2017).

Dermoscopy is the complementary evaluation method to the clinical evaluation of stretch marks in which a dermatoscope is used to evaluate skin lesions, offering a 10-fold magnification, allowing the evaluation of the structures of the epidermis, the dermoepidermal junction and the superficial papillary and reticular dermis. , not visible to the naked eye, in the red striae there is hypermelanosis and in the striae alba there is secondary leukoderma and reduced melanocytes. Epi-luminescence colorimetry is an evaluation method in which an epi-luminescence colorimeter coupled to a computer is used to measure the color of streaks in small, defined areas (AL-HIMDANI *et. al.*, 2014; LOPES, 2017).

In Confocal Reflection Microscopy, a point source of light is used to illuminate a small area and photograph it, making it possible to visualize the collagen and elastin fibers. In areas with stretch marks, the skin is more rough than the adjacent skin. It is possible to obtain images of the epidermis and superficial and deep papillary and reticular dermis. With the Primos 3D camera it is possible to produce a 3D image, and thus evaluate the topography of the surface of the skin, dermis and hypodermis (AL-HIMDANI *et. al.*, 2014; LOPES, 2017).

Photodocumentation has been used during the analysis of pre- and post-treatment conditions, allowing monitoring of the response to the treatment carried out and demonstrating the results for the patient. Scientific photography is a standard, non-invasive, fast, low-cost, accurate and easy-to-use method for monitoring the area of an injury, requiring a camera and a computer with software to archive the images. Professionals in the aesthetics area use photographic records due to the easy access to information when presenting treatment results to their patients, also presenting versatility in academic studies. Precautions must be taken to take good images, paying attention to the camera, which must be of good quality and be positioned in a fixed location, the location and adequate lighting. The use of flash can compromise the image (RODRIGUES *et. al.*, 2013; ALGHAMDI *et. al.*, 2012; TABERNER; CONTESTÍ, 2010; COSTA, 2016; TAHERI; YENTZER; FELDMAN, 2013).

2.4.6 Strategies to prevent and/or delay Cutaneous Stretch Marks

It is essential to prevent and/or delay the appearance of stretch marks. Some topical cosmetics can be used to maintain skin elasticity and hydration. Specific products are used for each type of stretch mark and each skin phototype. In the stria rubra it is possible to reduce erythema, edema and irritation and in the stria alba it is possible to increase the production of collagen, elastic fibers, improve hydration and reduce inflammation. Topical cosmetics used to prevent stretch marks generally have an emollient action as they contain lipid components such as oils, waxes, extracts with phytosteroids, among others, and a nourishing action capable of regenerating tissue, such as hyaluronic acid and vitamins and finally a repairing action, as antioxidants. Some active ingredients can bring benefits in the treatment and prevention of stretch marks, such as cocoa butter, centella asiatica, almond oil, lanolin, stearin, triethanolamine, glycerin and hydrolyzed collagen (LOPES, 2017; RIBEIRO *et. al.*, 2015; COSTA, 2016; WANG *et. al.*, 2015; BUCHANAN; FLETCHER; REID, 2010; MOORE; KELSBERG; SAFRANEK, 2012; SOLTANIPOUR, *et. al.*, 2014; TAAVONI *et. al.*, 2011; HERNANDEZ *et. al.*, 2013).

2.4.7 Treatment for stretch marks

There are several therapeutic procedures recommended to alleviate the appearance of stretch marks, but there is still no standard treatment that is capable of completely eliminating stretch marks. Approaches carried out during the initial stage have better results because when stretch marks progress to the final stage, it becomes difficult to alleviate their appearance. It is essential to correctly manage expectations regarding the results of the treatment, patients must be aware of the possible results and their individual characteristics, in addition to pre- and post-treatment care, possible side effects of the procedure and the importance of using sunscreen (SOLTANIPOUR et al, 2012; *et. al.*, 2017; KAUSHIK; ALEXIS, 2017).

Among the most used procedures in the treatment of stretch marks are ablative and non-ablative fractional lasers, whose mechanism of action is the stimulation of collagen production, it removes the epidermis and causes damage to the dermis, promoting collagen regeneration. Fractional lasers target specific areas causing damage to specific tissues, while traditional lasers target a larger area of skin. Ablative fractional lasers (LFA) have wavelengths between 2,940 nm and 10,600 nm, resulting in full thickness destruction of the skin. They are associated with deeper interventions, requiring a longer recovery period and increasing the risk of complications in patients with phototypes IV to VI. This study will focus on the study of the fractional carbon dioxide (CO₂) laser (KAUSHIK; ALEXIS, 2017).

2.4.7.1 Fractional carbon dioxide (CO₂) laser

This type of laser is efficient in healing processes as it interferes with the epidermal layer and thus penetrates deeply into the dermis. Ablation and tissue coagulation encourage neocollagenesis and elastin deposition during healing. It presents a risk of post-inflammatory hyperpigmentation, especially in higher phototypes. The CO₂ laser appears as an option for the treatment of cutaneous stretch marks, especially atrophic stretch marks, despite reports of considerable side effects such as pain, hyperpigmentation, erythema and post-intervention crust, these effects are well accepted by patients. Compared to non-ablative lasers, the CO₂ laser is more painful and requires

longer recovery times (ALDAHAN, *et. al.*, 2016; AL-HIMDANI *et. al.*, 2014; HAGUE; BAYAT, 2017; YANG; LEE *et. al.*, 2011; LOPES, 2017).

Lee et al (2010), carried out a study with the 10,600nm CO₂ fractional laser on volunteers with stretch marks, there was a huge improvement in half of the volunteers, however some presented hyperpigmentation, erythema and crusts after the procedure. The study carried out by Marques *et. al.*(2012) regarding the fractional CO₂ laser for the treatment of stretch marks, demonstrate an increase in the thickness of the epidermis, and an increase in the amount of collagen and elastic fibers after treatment. suggesting that this procedure would be a promising option for the treatment of stretch marks due to the dermal remodeling it causes (MARQUESE *et. al.*, 2012).

Among the therapeutic resources of electrotherapy, fractional ablative lasers are those that presented the greatest side effects, however these effects tend to be recovered weeks after the end of the treatment. Among the effects found, we can mention edema, erythema and hyperpigmentation. The use of a therapeutic laser contributes to the healing process, as it stimulates the production of ATP, which enhances mitotic and mitochondrial activity, which ultimately favors protein synthesis, enabling the regeneration of tissues affected by stretch marks. Subsequently, there is the stimulation of microcirculation and nutritional support that encourages an increase in mitotic speed, multiplying cells. And finally, vascular neoformation and the vasodilation process occur (CROCCO; MANTOVANI; VOLPINI, 2012; LEE *et. al.*, 2010; SHIN *et. al.*, 2011).

Ablative lasers are effective in healing, as they cause damage to the epidermal layer and penetrate into the deep dermis. Tissue ablation and coagulation stimulate neocollagenesis and elastin deposition during healing. However, caution is needed when treating patients with high phototypes, as they are at greater risk of post-inflammatory hyperpigmentation (YANG; LEE, 2011; SAVAS *et. al.*, 2014; SHUN *et. al.*, 2011).

2.4.7.1.1 Fractional CO₂ laser application method

The patient's skin to be treated needs to be prepared at least 15 days before the procedure with the triple formula containing 0.05% tretinoin, 4% hydroquinone and 0.01% fluocinolone acetonide. -

herpetic disease, with acyclovir 400mg 8/8h started one day before the procedure and maintained for five days. It is recommended to apply a topical anesthetic to the area 30 to 45 minutes before the procedure, which must be removed before applying the Laser. The device must be calibrated to a power of 30mj and then the laser must be applied along the length of the stretch mark. After the procedure, the patient should be instructed to wash the area twice a day and apply solid petroleum jelly to it for five days (YANG; LEE, 2011; SAVAS, *et. al.*, 2014; SHUN *et. al.*, 2011).

2.4.7.1.2 Precautions and contraindications when using fractional co2 laser

Several criteria must be observed before starting treatment with the fractional CO2 Laser in order to avoid complications. If the patient has hormonal changes, the treatment must be discontinued, as these changes may be related to the appearance of stretch marks. It is contraindicated for pregnant women and recent postpartum women, and the return of hormonal levels prior to pregnancy must be respected. During puberty, treatment is avoided as it is a period with major hormonal changes (BORGES, 2010; YANG; LEE, 2011; SAVAS *et. al.*, 2014; SHUN *et. al.*, 2011).

Patients with a pacemaker and uncontrolled chronic diseases, diabetes, hemophilia, steroid and anti-inflammatories should also avoid therapy, as in these conditions there may be a change in the inflammatory response different from that expected with the use of the fractional CO2 laser. People prone to developing keloids and hypertrophic scars should also not be treated with the laser (BORGES, 2010; YANG; LEE, 2011; SAVAS *et. al.*, 2014; SHUN *et. al.*, 2011).

2.4.7.1.3 Complications after application of fractional CO2 laser

After the procedure, mild complications such as erythema, superficial and acne-shaped eruptions, purpura and edema may appear, these generally tend to disappear within a few days after the procedure. There are also so-called moderate complications, such as infection, pigmentary changes, eruptive keratoacanthomas and anesthesia toxicity, these must be assessed carefully regarding the need for medical or drug intervention. Serious complications are scarring and disseminated infection. The patient

Those who show any sign of infection should be referred for immediate medical care (BORGES, 2010; YANG; LEE, 2011; SAVAS*et. al.*, 2014; SHUN*et. al.*, 2011).

At the time of laser application, the sensation is of intense heat, with moderate discomfort, 24 to 48 hours after the procedure there may be an intense burning sensation in the area with redness, local swelling may occur and irregular darkening is observed with a touch "rough" skin. After 72 hours, the surface layer peels off and the skin recovers in approximately 7 days. The results of collagen stimulation and re-epithelialization appear in approximately 30 days. The side effect after the fractional CO₂ laser most reported in the literature is post-inflammatory hyperpigmentation, more common in higher phototypes and with more aggressive parameters. This complication can be avoided by using a triple formula in skin preparation and by using more aggressive parameters only focally on the stretch marks (BORGES, 2010; YANG; LEE, 2011; SAVAS*et. al.*, 2014; SHUN*et. al.*, 2011).

3 METHODOLOGY

For the present study, the following procedures were carried out: A bibliographical search was carried out in the main databases: Virtual Health Library (VHL); Scientific Electronic Library Online (SciELO) and Lilacs. Bearing in mind that the purpose of this work is to carry out an evaluative approach to the effectiveness and benefits of the fractional CO₂ laser in the treatment of red and white stretch marks, describe its mechanism of action and analyze the results presented in the scientific literature. The following keywords were used: anatomy, histology and physiology of epithelial tissue; tissue repair; elasticity of epithelial tissue; stretch marks and fractional co₂ laser. The bibliographical research was carried out in the period between December 1, 2020 and February 10, 2021, for materials published in the last 10 years. For inclusion criteria, the materials should relate to epithelial tissue, striae and fractional co₂ laser to present the introduction and justification, theoretical review and conclusion of the present work. Materials located in the bibliographic research that did not meet any of the previously described criteria or that did not have references available were not selected for inclusion in this work.

4 RESULTS AND DISCUSSIONS

4.1 EFFECTIVENESS OF CO₂ LASER IN THE TREATMENT OF RUBBER AND BLACK STRETCHMARKS

Analysis of the current literature demonstrates that in general fractional lasers appear to be the most promising alternative in the treatment of stretch marks because they can evenly distribute the energy and also limit the treatment area to within the margin of the stretch mark. Stretch marks can be successfully treated with a variety of fractionated and non-fractionated lasers, although there are insufficient comparative studies to decide which laser parameters are most effective. Combined treatments may produce better clinical results with fewer adverse effects, but further large-scale randomized clinical trials will be needed to validate their use in practice.

The non-ablative fractional laser can lead to better results for distended stretch marks, in addition to earlier recovery than with ablative lasers. Therefore, the 1,540-nm non-ablative fractional laser has proven to be a relevant therapeutic modality as a front line in the fight against stretch marks. However, larger future studies are needed to standardize protocols. Future researchers should consider including larger sampling, long-term randomized comparative studies, with objective outcome measures such as skin biopsies and molecular studies demonstrating an increase in collagen and elastin fibers that correlate with clinical improvements.

FINAL CONSIDERATIONS

It is concluded that there is little literature on the therapeutic resources used to treat stretch marks. There is a need for more research on this topic, as stretch marks continue to be an important target of investigation and perhaps studies on the stimulation of dermal remodeling will contribute to the elucidation of these skin changes. Therapeutic resources, used correctly by appropriate professionals, generate positive and satisfactory results.

There are many causes for the appearance of stretch marks on the human body, making it a pathology without distinction of gender or age. There are several aesthetic treatments to treat

However, there are no studies that prove its effectiveness in completely disappearing stretch marks. These techniques can be used both together and separately. It is up to the aesthetics professional to correctly evaluate and recommend the most appropriate treatment for each situation.

Treatments with new technologies are gaining more space and are less dependent on doctors, as they use parameters pre-established by the device manufacturers. However, it is necessary to highlight that the treatment of stretch marks is multimodal and varied, with better responses with a combination of techniques, with the fractional CO₂ laser also playing its role, with excellent results. The fractional CO₂ laser has proven to be a safe and effective option for treating stretch marks.

The prevention and treatment of stretch marks remains a clinical challenge as evidenced by the variety of alternative methods that exist to prevent and treat stretch marks. Limitations include few randomized controlled trials evaluating long-term efficacy and safety that compare different treatment modalities using universally validated standardized assessment methods. Non-ablative fractional lasers, especially the 1,540-nm laser, stand out as an interesting therapeutic modality for the treatment of stretch marks. This study did not intend to exhaust this subject, other research must be carried out to continue, as this study is relevant and new research must be carried out seeking this understanding.

REFERENCES

ALBUQUERQUE, AGet. *a*/.Effects of therapeutic laser on the burn healing process: a literature review.**Brazilian Journal of Burns**, v. 9, no. 1, p. 21-30, 2010.

ALDAHAN, ASet. *a*/.Laser and light treatments for striae distensae: a comprehensive review of the literature.**American journal of clinical dermatology**, v. 17, no. 3, p. 239-256, 2016.

ALGHAMDI, KMet. *a*/.Assessment methods for the evaluation of vitiligo.**Journal of the European Academy of Dermatology and Venereology**, v. 26, no. 12, p. 1463-1471, 2012.

AL-HIMDANI, S.et. *a*/.Striae distensae: a comprehensive review and evidence-based evaluation of prophylaxis and treatment.**British Journal of Dermatology**, v. 170, n. 3, p. 527-547, 2014.

AZIZ, J.*et. al.* Molecular mechanisms of stress-responsive changes in collagen and elastin networks in skin. **Skin pharmacology and physiology**, v. 29, no. 4, p. 190-203, 2016.

BORGES, F. dos S.; SCORZA, FA; JAHARA, RSTherapeutic modalities for aesthetic dysfunctions. São Paulo. Phortes, 2010. Paulo.

BUCHANAN, K.; FLETCHER, HM; REID, M. Prevention of striae gravidarum with coconut butter cream. **International Journal of Gynecology & Obstetrics**, v. 108, no. 1, p. 65-68, 2010.

CAUSSA, Jordi Esquirol; VILA, Elisabeth Herrero. Epidermal growth factor, innovation and safety. **Med. clin (Print. edition)**, P. 305-312, 2015.

COSTA, CF of CSUse of microgalvanic current for the development of two protocols for treating striae alba. 2016. Master's Thesis. Federal Technological University of Paraná.

CROCCO, EI; MANTOVANI, PA; VOLPINI, BM Fornazier. In search of treatments for Striae Rubra and Striae Alba: the dermatologist's challenge. **Surgical & cosmetic dermatology**, v. 4, no. 4, p. 332-337, 2012.

DA COSTA, RS Main Methods for Aesthetic Treatment of Stretch Marks. **Institute of Higher Education and Research**. Recife, 2016.

DANTAS, J.B. **An essay on the cult of the body in contemporary times**. 2011.

DEVILLERS, C.*et. al.* High resolution skin colorimetry, strain mapping and mechanobiology. **International journal of cosmetic science**, v. 32, no. 4, p. 241-245, 2010.

DOS REIS, CT; VIERA, EK Therapeutic resources in the treatment of stretch marks. **Integrated health magazine**, v. 11, no. 22, p. 59-70, 2018.

EL TAIEB, MA; IBRAHIM, AK Fractional CO2 laser versus intense pulsed light in treating striae distensae. **Indian journal of dermatology**, v. 61, no. 2, p. 174, 2016.

ERSOY, E.*et. al.* Is it possible to prevent striae gravidarum? **Journal of the Chinese Medical Association**, v. 79, no. 5, p. 272-275, 2016.

FAAD, DSS MD. Therapeutic update on the treatment of striae distensae. **J Drugs Dermatol**, v. 14, no. 1, p. 11-12, 2015.

FARAHNIK, B.*et. al.* Striae gravidarum: Risk factors, prevention, and management. **International journal of women's dermatology**, v. 3, no. 2, p. 77-85, 2017.

FONTENELE, FC; CARDOSO, MVLML Skin lesions in newborns in the hospital environment: type, size and affected area. **USP Nursing School Magazine**, v. 45, no. 1, p. 130-137, 2011.

GILMORE, S.J.*et. al.*A mechanochemical model of striae distensae.**Mathematical biosciences**, v. 240, no. 2, p. 141-147, 2012.

GONÇALVES, GR*et. al.*Benefits of ingesting collagen for the human body.**Electronic Journal of Biology (REB). ISSN 1983-7682**, v. 8, no. 2, p. 190-206, 2015.

GONDIM, R. M. F.**Assessment of skin healing: fluorescence and stereology**. 2012. Doctoral Thesis. University of Sao Paulo.

HAGUE, A.; BAYAT, A. Therapeutic targets in the management of striae distensae: A systematic review.**Journal of the American Academy of Dermatology**, v. 77, no. 3, p. 559- 568. e18, 2017.

HERNÁNDEZ, J. Á.*et. al.*Use of a specific anti-stretch mark cream for preventing or reducing the severity of striae gravidarum. Randomized, double-blind, controlled trial. **International journal of cosmetic science**, v. 35, no. 3, p. 233-237, 2013.

HWANG, K.-A.; YI, Bo-Rim; CHOI, K.-C. Molecular mechanisms and in vivo mouse models of skin aging associated with dermal matrix alterations.**Laboratory animal research**, v. 27, no. 1, p. 1, 2011.

KASIELSKA-TROJAN, A.; SOBCZAK, M.; ANTOSZEWSKI, B. Risk factors of striae gravidarum.**International journal of cosmetic science**, v. 37, no. 2, p. 236-240, 2015.

KAUSHIK, SB; ALEXIS, AF Nonablative fractional laser resurfacing in skin of color: evidence-based review.**The Journal of clinical and aesthetic dermatology**, v. 10, no. 6, p. 51, 2017.

KHAVKIN, J.; ELLIS, DAF Aging skin: histology, physiology, and pathology.**Facial Plastic Surgery Clinics**, v. 19, no. 2, p. 229-234, 2011.

LEDOUX, M.*et. al.*A case-control study of cutaneous signs in adult patients with Marfan disease: diagnostic value of striae.**Journal of the American Academy of Dermatology**, v. 64, no. 2, p. 290-295, 2011.

LEE, S.E.*et. al.*Treatment of striae distensae using an ablative 10,600-nm carbon dioxide fractional laser: a retrospective review of 27 participants.**Dermatologic surgery**, v. 36, no. 11, p. 1683-1690, 2010.

LOPES, IF**Skin stretch marks**:process, strategies to prevent and delay the onset. 2017. Doctoral Thesis.

MAY, M.**Aesthetic Medicine Treatise**. 2nd ed. 3.vol. São Paulo: Roca, 2011.

MARQUES, E.*et. al.*Twenty-four months of clinical follow-up for the treatment of striae distendae using fractional CO2 laser in 200 Brazilian participants using a new three-dimensional

photography documentation. **Journal of the American Academy of Dermatology**, v. 66, no. 4, 2012.

MOORE, J.; KELSBERG, G.; SAFRANEK, S. Do any topical agents help prevent or reduce stretch marks? 2012.

NARIN, R. *et. al.* Can different geographic conditions affect the formation of striae gravidarum? A multicentric study. **Journal of Obstetrics and Gynecology Research**, v. 41, no. 9, p. 1377-1383, 2015.

NAYLOR, EC; WATSON, RE B; SHERRATT, MJ Molecular aspects of skin aging. **Maturitas**, v. 69, no. 3, p. 249-256, 2011.

NEPOMUCENO, AC; DA-SILVA, LC Laser treatment for stretch marks: literature review. **Rev. bras. cir. plastic**, P. 580-585, 2018.

PARK, KY *et. al.* Treatment of striae distensae using needling therapy: a pilot study. **Dermatologic surgery**, v. 38, no. 11, p. 1823-1828, 2012.

PETROSKI, EL; PELEGRINI, A.; GLANER, MF Reasons and prevalence of dissatisfaction with body image in adolescents. **Science & Public Health**, v. 17, no. 4, p. 1071- 1077, 2012.

EDUCATION PORTAL, **Tissue repair process**—aesthetics. Available at: <https://siteantigo.portaleducacao.com.br/conteudo/artigos/estetica/processo-de-reparotecidual/31783#>. Accessed on 10 Feb. 2021.

QUEIROZ, SKD; RODRIGUES, G. de SC; DE CONTI, MHS Microneedling technique in the treatment of stretch marks: a literature review. **Brazilian Journal of Development**, v. 7, no. 1, p. 4497-4519, 2021.

REZENDE, PP; PINHEIRO, NM; MENDONÇA, AC Therapeutic resources for treating stretch marks: a systematic review. **JBCS**, v. 1, no. 3, p. 59-67, 2016.

RIBEIRO, A *Set. al.* Main benefits and applicability of plant extracts in skin care products. **Cosmetics**, v. 2, no. 2, p. 48-65, 2015.

RODRIGUES, DF *et. al.* The Image j program as a tool for morphometric analysis of skin wounds. 2013.

ROLFE, H.; WURM, E.; GILMORE, S. An investigation of striae distensae using reflectance confocal microscopy. **Australasian journal of dermatology**, v. 53, no. 3, p. 181-185, 2012.

ROSS, N.A. *et. al.* Striae distensae: preventative and therapeutic modalities to improve aesthetic appearance. **Dermatologic Surgery**, v. 43, no. 5, p. 635-648, 2017.

SAVAS, JA *et. al.* Lasers and lights for the treatment of striae distensae. **Lasers in medical science**, v. 29, no. 5, p. 1735-1743, 2014.

SHIN, JU *et. al.* The effect of succinylated atelocollagen and ablative fractional resurfacing laser on striae distensae. **Journal of Dermatological Treatment**, v. 22, no. 2, p. 113-121, 2011.

SOLTANIPOUR, F. *et. al.* The effect of olive oil and the Saj® cream in prevention of striae gravidarum: A randomized controlled clinical trial. **Complementary therapies in medicine**, v. 22, no. 2, p. 220-225, 2014.

TAAVONI, S. *et. al.* Effects of olive oil on striae gravidarum in the second trimester of pregnancy. **Complementary Therapies in Clinical Practice**, v. 17, no. 3, p. 167-169, 2011.

TABERNER, R.; CONTESTÍ, T. Digital photograph storage systems in clinical dermatology. **Dermo-Syphiologic Acts (English Edition)**, v. 101, no. 4, p. 307-314, 2010.

TACANI, RE; TACANI, PM Manual techniques in unsightly conditions. **Aesthetic medicine treatise**. 2nd ed. São Paulo: Roca, p. 1511-50, 2011.

TAHERI, A.; YENTZER, BA; FELDMAN, SR Focusing and depth of field in photography: application in dermatology practice. **Skin Research and Technology**, v. 19, no. 4, p. 394-397, 2013.

UD-DIN, S.; MCGEORGE, D.; BAYAT, A. Topical management of striae distensae (stretch marks): prevention and therapy of striae rubrae and albae. **Journal of the European academy of dermatology and venereology**, v. 30, no. 2, p. 211-222, 2016.

UD-DIN, S. *et. al.* A double-blind controlled clinical trial assessing the effect of topical gels on striae distensae (stretch marks): a non-invasive imaging, morphological and immunohistochemical study. **Archives of dermatological research**, v. 305, n. 7, p. 603-617, 2013.

VENUS, M.; WATERMAN, J.; MCNAB, I. Basic physiology of the skin. **Surgery (Oxford)**, v. 28, no. 10, p. 469-472, 2010.

VORA, RV *et. al.* Pregnancy and skin. **Journal of family medicine and primary care**, v. 3, no. 4, p. 318, 2014.

WANG, F. *et. al.* Marked disruption and aberrant regulation of elastic fibers in early striae gravidarum. **British Journal of Dermatology**, v. 173, no. 6, p. 1420-1430, 2015.

YANG, YJ; LEE, Ga-Y. Treatment of striae distensae with nonablative fractional laser versus ablative CO2 fractional laser: a randomized controlled trial. **Annals of dermatology**, v. 23, no. 4, p. 481, 2011.